



Histopathological View of Benign Essential Blepharospasm: Orbicularis Oculi Hormone Receptor Levels

Kubra Serefoglu Cabuk,¹ Ganime Coban,² Gulay Yalcinkaya Cakir,³ Zeynep Sezal Serefoglu,² Senay Asik Nacaroglu,⁴ Gamze Ozturk Karabulut,⁵ Korhan Fazil⁶

¹University of Health Sciences Beyoglu Eye Training and Research Hospital, Istanbul, Türkiye

²Department of Pathology, Bezmialem Vakif University, Faculty of Medicine, Istanbul, Türkiye

³Department of Ophthalmology, Patnos State Hospital, Agri, Türkiye

⁴Department of Ophthalmology, Istanbul Medipol University, Istanbul, Türkiye

⁵Department of Ophthalmology, Arel University, Memorial Hospital, Istanbul, Türkiye

⁶Oculoplastic and Orbital Surgery and Ocular Oncology Center, Istanbul, Türkiye

Abstract

Objectives: Benign essential blepharospasm (BEB) is a focal dystonia characterized by involuntary contractions of the orbicularis oculi and periocular muscles. We aimed to investigate the effects of muscle receptor levels on the etiopathogenesis of blepharospasm by evaluating the orbicularis oculi estrogen receptor (ER) and androgen receptor (AR) levels.

Methods: Four blepharospasm patients (2 females and 2 males) who underwent upper lid blepharoplasty and/or orbicularis myomectomy and 4 healthy cases (2 females, 2 males) that had upper lid blepharoplasty were included. The pretarsal, preseptal, and orbital parts of the orbicularis muscles of the patients who underwent orbicularis myomectomy and the waste muscle tissue materials taken from the preseptal orbicularis muscles of the patients who had only upper blepharoplasty were analyzed. Immunohistochemical staining was performed with estrogen alpha and androgen.

Results: In healthy men, the orbicularis oculi muscle was stained with ER at a moderate intensity and with AR at a high intensity. In men with blepharospasm, the orbicularis oculi were not stained with ER at all, but at a high intensity with AR. In healthy women, the orbicularis oculi were stained with ER and AR at a high intensity (>50%). In women with blepharospasm, the staining intensities of both receptors were moderate.

Conclusion: We determined a decrease in ER and AR in females and almost the absence of ER in males with BEB. This decrease in ER may be associated with a functional abnormality in mitochondria and the decrease in hormonal receptors may be associated with sarcopenia in orbicularis oculi muscle fibers.

Keywords: Androgen receptor, benign essential blepharospasm, estrogen receptor, hormone receptor, orbicularis oculi

Introduction

Benign essential blepharospasm (BEB) is a focal dystonia characterized by involuntary contractions of the orbicularis oculi and periocular muscles. Symptoms generally range from

mildly increased blink rate to vigorous eyelid closure occasionally causing functional blindness. The majority of patients also suffer from the symptoms of dry eyes, irritation, and photophobia at the time of presentation (1). This disease of-

How to cite this article: Serefoglu Cabuk K, Coban G, Yalcinkaya Cakir G, Sezal Serefoglu Z, Asik Nacaroglu S, Ozturk Karabulut G, et al. Histopathological View of Benign Essential Blepharospasm: Orbicularis Oculi Hormone Receptor Levels. *Beyoglu Eye J* 2023; 8(2): 110-114.

Address for correspondence: Gulay Yalcinkaya Cakir, MD. Department of Ophthalmology, Patnos State Hospital, Agri, Türkiye
Phone: +90 506 594 22 06 **E-mail:** ykgulay@gmail.com

Submitted Date: January 08, 2023 **Revised Date:** March 20, 2023 **Accepted Date:** April 04, 2023 **Available Online Date:** May 01, 2023

Beyoglu Eye Training and Research Hospital - Available online at www.beyoglueye.com

OPEN ACCESS This is an open access article under the CC BY-NC license (<http://creativecommons.org/licenses/by-nc/4.0/>).



ten affects middle-aged and older women. The female/male ratio was reported as 3/1 or 1.8/1 (2,3). However, the reason for this gender distribution has not been revealed so far (4).

The effects of estrogen receptors (ERs) and androgen receptors (ARs) in striated muscle functions are known clearly (5,6). By aging, decreased hormone levels are associated with the loss of muscle strength (sarcopenia) (7). Some diseases with different gender distributions are related to the ER levels of the relevant tissue (8,9).

This study aims to investigate whether muscle receptor levels affect the etiopathogenesis of blepharospasm by evaluating the orbicularis oculi AR and ER levels in healthy individuals and patients with BEB.

Methods

The study was approved by the University of Health Sciences Hamidiye ethics committee (date: December 18, 2020, number: 28/5) and adhered to the tenets of the Declaration of Helsinki.

Four BEB patients (2 females and 2 males) who underwent upper lid blepharoplasty and/or orbicularis myomectomy and 4 healthy controls (2 females 2 males) with similar ages who underwent upper lid blepharoplasty were included in the study. The frequency and severity of blepharospasm were evaluated using the Jankovic Rating Scale (2). Disease duration and botulinum toxin administration times were noted from the patients' medical records.

The pretarsal, preseptal, and orbital parts of the orbicularis muscles of the patients who underwent orbicularis myomectomy (n=2) and the waste muscle tissue materials taken from the preseptal orbicularis muscles of the patients who had only upper blepharoplasty were placed in 10% formaldehyde solution.

Immunohistochemical staining was performed with estrogen alpha and androgen. Staining intensity was classified as 0: no staining, 1: weak staining, 2: moderate staining, 3: strong staining, and the percentages of staining were defined as 0: no staining, 1: between 1 and 25%, 2: between 25 and 50%, 3: over 50%. The staining intensities of the control group and BEB patients were compared by two blinded pathologists and the average results were noted.

Statistical Analysis

The Statistical Package for the Social Sciences was used to conduct the statistical analysis (SPSS, v.20, Chicago, IL, USA). According to the Shapiro–Wilk test, all of the data were normally distributed. The parameters were given as mean±standard deviation. Statistical significance was set at $p<0.05$.

Results

All women were in the post-menopausal period. None of the subjects had used medication other than artificial tears (Hy-

onat, Vem Pharmaceuticals, Ankara, Turkey) and botulinum toxin (Dysport, Medicis Pharmaceutical Corp., Scottsdale, AZ, USA). The mean disease duration was 60.50 ± 47.54 months (min: 25 and max: 135) for BEB patients. The mean botulinum toxin administration time was 51.25 ± 47.30 months (min: 16 and max: 126). Botulinum administration intervals were 4 months for all BEB patients. According to the Jankovic Rating Scale, the mean severity and frequency of blepharospasm were 3.25 ± 0.46 and 3.75 ± 0.46 , respectively.

In healthy men, the preseptal orbicularis oculi muscle was stained with ER at a moderate intensity and with AR at a high intensity. In men with BEB, it was observed that the preseptal and pretarsal parts of the orbicularis oculi were not stained with ER at all, but at high intensity with AR. In healthy women, the orbicularis oculi were stained with ER and AR at a high intensity (>50%). In women with BEB, the staining intensity of both receptors was moderate.

The demographic features of the participants and the results of staining are summarized in Table 1, and the staining degree and percentage of orbicularis oculi muscle of some participants with ER or AR are summarized in Figure 1.

Discussion

In this study, we investigated the role of estrogen and ARs in the pathophysiological alterations of the orbicularis oculi muscle in BEB. We also hypothesized that the female predominance in BEB may also be associated with the ER and AR levels. The absence of the ERs in male patients with BEB while its presence in the control cases supports our hypothesis that the receptor distribution may affect the disease development. Similarly, decreased ER and AR levels in female BEB patients compared with the control cases also support the hypothesis.

From a pathophysiological perspective, BEB is considered to be due to altered functional connectivity in basal ganglia, cerebellum, primary/secondary sensorimotor cortex, and visual areas resulting in involuntary contraction of orbicularis oculi and periorbicular muscles (10,11). However, today, the most effective treatment remains symptomatic as repeated botulinum toxin injections to periocular muscles (12).

Estrogen actions essentially result from the activation of two molecular targets, the ERs alpha (ER α) and beta (ER β) (13). It is known that the ER α is concentrated in female reproductive organs, especially the uterus, breast tissue, and hypothalamus (5). Estrogen is known to have an important role in the exercise capacity of the skeletal muscle, and in postmenopausal women, estrogen decline causes decreased muscle mass and strength which is associated with sarcopenia (5). In an experimental study, skeletal muscle-specific ER α deletion resulted in muscle weakness, suggesting the beneficial effects of estradiol on muscle strength through

Table 1. The demographic features of the participants and the results of staining

| | Age (years) | Gender | ER staining degree | ER staining percentage | AR staining degree | AR staining percentage |
|---------------|-------------|--------|--------------------|------------------------|--------------------|------------------------|
| Blepharospasm | 70 | Male | 0 | 0 | 3 | 3 |
| | 52 | Male | 0 | 0 | 3 | 3 |
| Control | 70 | Male | 2 | 3 | 3 | 3 |
| | 55 | Male | 2 | 2 | 3 | 3 |
| Blepharospasm | 64 | Female | 2 | 3 | 2 | 3 |
| | 66 | Female | 2 | 2 | 2 | 3 |
| Control | 62 | Female | 3 | 3 | 3 | 3 |
| | 66 | Female | 3 | 3 | 3 | 3 |

ER: Estrogen receptor; AR: Androgen receptor. Staining intensity was classified as; 0: no staining, 1: weak staining, 2: moderate staining, 3: severe staining, and the percentage of staining were defined as 0: no staining, 1: between 1-2%, 2: between 25-50%, 3: over 50%.

ER α (14). On the other hand, in another experimental study, ER activation by estradiol treatment resulted in the maintenance of skeletal muscle mass in orchidectomized male mice;

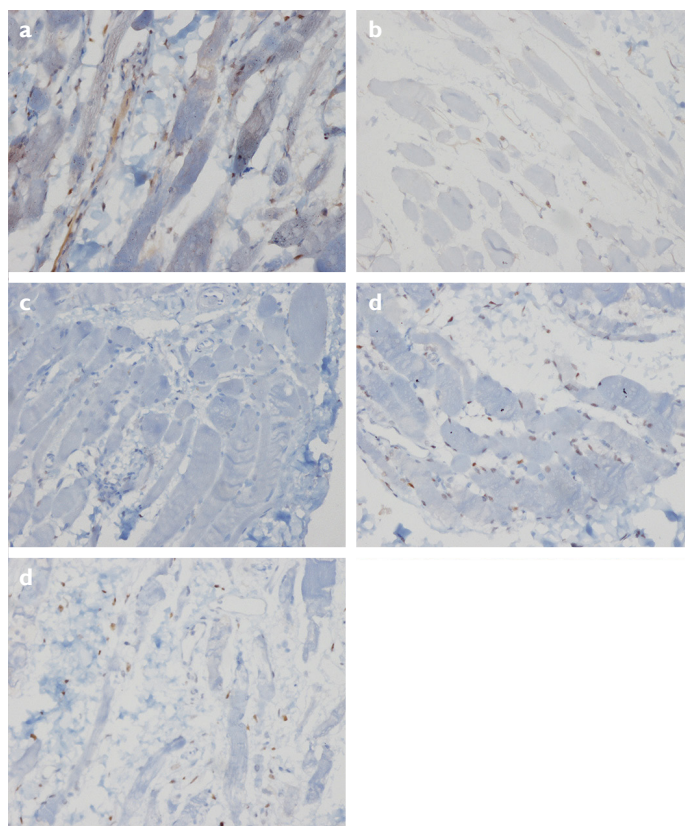


Figure 1. Histopathological image of the orbicularis oculi muscle with immunohistochemical staining with estrogen alpha and androgen receptors. A. Control group estrogen receptor (ER) (3: Severe, 3: >50% staining, $\times 200$) B. Control group ER (2: Moderate, 2: Between 25 and 50% staining, $\times 200$) C. Blepharospasm patient ER (0: No staining, $\times 200$) D. Control group androgen receptor (AR) (3: Severe, 3: >50% staining, $\times 200$) E. Blepharospasm AR (2: Moderate, 2: Between 25 and 50% staining).

however, this effect was less marked than that of AR activation by dihydrotestosterone treatment (15).

In both male and female mice, it was determined that ER plays a key role in optimal mitochondrial oxidative potential and muscle fitness (16). In mitochondria of skeletal muscle cells, estrogens modulate protein content and specific activity of mitochondrial proteins, phospholipid content of membranes, oxidant and anti-oxidant capacities, oxidative phosphorylation, and calcium retention capacities (17). Some aspects of mitochondrial quality appear to be inherently different between males and females and may contribute to the differential progression of mitochondria-related pathologies, including muscle atrophies (7). The decrease or lack of ERs in BEB patients may be associated with mitochondrial dysfunction in the orbicularis oculi muscle.

ER α is the main mediator of metabolic and vascular effects of estrogens and it has been clearly shown that ER α has prominent nuclear effects against obesity, diabetes, and atheroma. These effects are mediated by some of the anti-oxidant functions of estrogen such as nitric oxide release or re-endothelialization (18). The decrease in the anti-oxidant effects of ER may be associated with BEB development.

Androgens are known to have anabolic and anti-catabolic effects in striated muscles by protecting myoblasts and suppressing atrophy pathways (19). The reduction of AR protein was reported in sarcopenia in male rat (20). Androgens decrease with age, although not as rapidly as estrogens in also females (21). In this process, atrophy and a decrease in the number of muscle fibers (sarcopenia) are more dominant in type II muscle fibers compared with type I (5,22). Orbicularis oculi are also a type II muscle fiber. Hence, it can be hypothesized that lower AR levels in female patients with BEB may cause a decrease in type 2 muscle fibers which requires further studies.

There are some limitations of this study that should be mentioned. The quantitative analysis could not be performed, and the receptor status of the normal orbicularis oculi muscle of the population was not known. Serum hormone levels were not studied in those patients. Moreover, BEB patients were not naive, since we could not exclude the patients to whom botulinum toxin was applied repeatedly. Therefore, it is not known whether this effect belongs to the toxin or the disease itself.

Conclusion

To the best of our knowledge, there is no study evaluating sex hormone levels in orbicularis oculi in patients with BEB. In this study, we determined a decrease in ERs and ARs in females and ERs in males with BEB. This decrease in ERs may be associated with a functional abnormality in mitochondria, and the decrease in hormonal receptors may be associated with sarcopenia in type 2 fibers of orbicularis oculi. Further studies are warranted to define the pathophysiological mechanisms of female predominance and the role of hormone replacement therapy or selective AR modulators in patients with BEB.

Disclosures

Ethics Committee Approval: The study was approved by the University of Health Sciences Hamidiye ethics committee (Date: December 18, 2020, number: 28/5) and adhered to the tenets of the Declaration of Helsinki.

Peer-review: Externally peer-reviewed.

Conflict of Interest: None declared.

Authorship Contributions: Concept – K.S.C., G.C.; Design – G.S.C., G.O.K.; Supervision – Ş.A.N., K.F.; Resource – G.C., Z.S.S.; Materials – K.S.C., G.C.; Data collection and/or processing – G.Y.C., Z.S.S.; Analysis and/or interpretation – G.C., Z.S.S.; Literature search – G.Y.C., K.S.C.; Writing – K.S.C., G.Y.C.; Critical review – G.O.K., K.F.

References

1. Evinger C, Bao JB, Powers AS, Kassem IS, Schicatano EJ, Henriquez VM, et al. Dry eye, blinking, and blepharospasm. *Mov Disord* 2002;17:S75–8. [CrossRef]
2. Jankovic J, Orman J. Blepharospasm: Demographic and clinical survey of 250 patients. *Ann Ophthalmol* 1984;16:371–6.
3. Lee MS, Johnson M, Harrison AR. Gender differences in benign essential blepharospasm. *Ophthalmic Plast Reconstr Surg* 2012;28:169–70. [CrossRef]
4. Zalyalova Z. Benign essential blepharospasm: epidemiology, clinical manifestations, pathophysiology, botulinum toxin therapy. *Neurol Neuropsychiatry Psychosom* 2021;13:119–25.
5. Ikeda K, Horie-Inoue K, Inoue S. Functions of estrogen and estrogen receptor signaling on skeletal muscle. *J Steroid Biochem Mol Biol* 2019;191:105375. [CrossRef]
6. Altuwajiri S, Lee DK, Chuang KH, Ting HJ, Yang Z, Xu Q, et al. Androgen receptor regulates expression of skeletal muscle-specific proteins and muscle cell types. *Endocrine* 2004;25:27–32. [CrossRef]
7. Rosa-Caldwell ME, Greene NP. Muscle metabolism and atrophy: Let's talk about sex. *Biol Sex Differ* 2019;10:43. [CrossRef]
8. Copas P, Bukovsky A, Asbury B, Elder RF, Caudle MR. Estrogen, progesterone, and androgen receptor expression in levator ani muscle and fascia. *J Womens Health Gend Based Med* 2001;10:785–95. [CrossRef]
9. Dave TV, Tiple S, Vempati S, Palo M, Ali MJ, Kaliki S, et al. Low-cost three-dimensional printed orbital template-assisted patient-specific implants for the correction of spherical orbital implant migration. *Indian J Ophthalmol* 2018;66:1600–7. [CrossRef]
10. Jochim A, Li Y, Gora-Stahlberg G, Mantel T, Berndt M, Castrop F, et al. Altered functional connectivity in blepharospasm/orofacial dystonia. *Brain Behav* 2018;8:e00894. [CrossRef]
11. Ni MF, Huang XF, Miao YW, Liang ZH. Resting state fMRI observations of baseline brain functional activities and connectivities in primary blepharospasm. *Neurosci Lett* 2017;660:22–8.
12. Mitsikostas DD, Dekundy A, Hanschmann A, Althaus M, Scheschonka A, Pagan F, et al. Duration and onset of effect of incobotulinumtoxinA for the treatment of blepharospasm in botulinum toxin-naïve subjects. *Curr Med Res Opin* 2021;37:1761–8. [CrossRef]
13. Mumford PW, Romero MA, Mao X, Mobley CB, Kephart WC, Haun CT, et al. Cross talk between androgen and Wnt signaling potentially contributes to age-related skeletal muscle atrophy in rats. *J Appl Physiol (1985)* 2018;125:486–94. [CrossRef]
14. Collins BC, Mader TL, Cabelka CA, Iñigo MR, Spangenburg EE, Lowe DA. Deletion of estrogen receptor α in skeletal muscle results in impaired contractility in female mice. *J Appl Physiol (1985)* 2018;124:980–92. [CrossRef]
15. Svensson J, Moverare-Skrtic S, Windahl S, Swanson C, Sjögren K. Stimulation of both estrogen and androgen receptors maintains skeletal muscle mass in gonadectomized male mice but mainly via different pathways. *J Mol Endocrinol* 2010;45:45–57.
16. Perry MC, Dufour CR, Tam IS, B'chir W, Giguère V. Estrogen-related receptor- α coordinates transcriptional programs essential for exercise tolerance and muscle fitness. *Mol Endocrinol* 2014;28:2060–71. [CrossRef]
17. Quartarone A, Sant'Angelo A, Battaglia F, Bagnato S, Rizzo V, Morgante F, et al. Enhanced long-term potentiation-like plasticity of the trigeminal blink reflex circuit in blepharospasm. *J Neurosci* 2006;26:716–21. [CrossRef]
18. Ascenzi P, Bocedi A, Marino M. Structure-function relationship of estrogen receptor alpha and beta: Impact on human health. *Mol Aspects Med* 2006;27:299–402. [CrossRef]
19. Ventura-Clapier R, Piquereau J, Veksler V, Garnier A. Estrogens, estrogen receptors effects on cardiac and skeletal muscle mitochondria. *Front Endocrinol (Lausanne)* 2019;10:557. [CrossRef]

20. Dreyer HC, Blanco CE, Sattler FR, Schroeder ET, Wiswell RA. Satellite cell numbers in young and older men 24 hours after eccentric exercise. *Muscle Nerve* 2006;33:242–53. [\[CrossRef\]](#)
21. Mezzullo M, Gambineri A, Di Dalmazi G, Fazzini A, Magagnoli M, Baccini M, et al. Steroid reference intervals in women: Influence of menopause, age and metabolism. *Eur J Endocrinol* 2021;184:395–407. [\[CrossRef\]](#)
22. Rana K, Davey RA, Zajac JD. Human androgen deficiency: Insights gained from androgen receptor knockout mouse models. *Asian J Androl* 2014;16:169–77. [\[CrossRef\]](#)

Copyright of Beyoglu Eye Journal is the property of KARE Publishing and its content may not be copied or emailed to multiple sites or posted to a listserv without the copyright holder's express written permission. However, users may print, download, or email articles for individual use.