

Immune histochemical study of KI-67 level and ribonucleic acid in the process of healing of burn wounds after treatment with drugs containing dexpanthenol and ceramide

Yaroslava Butko¹ , Oksana Tkachova¹ , Vera Ulanova¹ , Yeşim Müge Şahin² , Olha Levashova³ , Tetyana Tishakova^{3,*} 

¹National University of Pharmacy, 53, Pushkinska str., Kharkiv, 61002, Ukraine

²Istanbul Arel University Turkey, Faculty of Engineering, Biomedical Engineering Department, Polymer Technologies and Composite Application and Research Center, Türkoba Mahallesi Erguvan Sokak No:26 / K Villa A3 34537 Tepekent - Büyükçekmece/Istanbul, Turkey

³Kharkiv National Medical University, 4 Nauky Avenue, Kharkiv, 61022, Ukraine

*corresponding author e-mail address: ttishakova@ukr.net | [37028849800](https://doi.org/10.33263/BRIAC96.586590)

ABSTRACT

Ceramides are structural components of the stratum corneum that regulate cell proliferation and differentiation. The study of the effect of the cream containing dexpanthenol and ceramide on the proliferation processes and regeneration of burn wounds in rats. Experimental rats with III-A degree thermal burn were treated separately with the following preparations: cream with ceramides, cream with dexpanthenol and ceramides and cream "Bepanten". The proliferative-regenerative activity of the drugs was investigated by studying the content of the Ki-67 producing cells and the content of ribonucleic acid (RNA) in the cytoplasm of the granulation tissue fibroblasts. Ceramides contributed to wounds healing, increasing the content of Ki-67 antigenpositive cells, accelerating the formation of scar in the wound. The therapeutic effect of creams with ceramides exceeds the efficacy of the reference preparation "Bepanten" cream. The addition of ceramides to dexpanthenol increases the quality and reduces the wound healing time.

Keywords: burn wound; Ki-67; RNA; dexpanthenol, ceramides.

1. INTRODUCTION

Stimulation of burn wounds healing remains an important issue for medicine. According to the WHO: burns, traumas and other injuries occupy the third place in the population mortality. Burn wounds accounted for 14% of the overall structure of mortality and about 840 million people suffer from them every year in the world [1, 2]. In Ukraine, more than 100 000 cases of burn injury are registered annually, and 60-80% of those who have been burned have II-III degree burns of skin that do not require surgical intervention [3-6]. Thus, the prevalence of burn wounds and complications of their healing, insufficiently effective therapy, economic losses caused by temporary loss of working capacity of the patients require an in-depth study of such pathologies, improvement of existing methods and development of new methods of treatment.

The processes that arise in response to thermal damage combine the stress response of the blood system with the activation of the sympathoadrenal system, the development of a non-specific inflammatory and immune reaction with the transition to structural and metabolic disorders of organs, tissues and systems, damage to cell membranes and the strengthening of catabolic processes.

Fibroblasts play a decisive role in the construction of granulation tissue in the regeneration phase because they synthesize the components of intercellular substance of the connective tissue and protein precursors of collagen [7-9]. Synthesis of collagen begins with the formation of the

corresponding ribonucleic acid (RNA), translation and formation of collagen fibers, which affect the strength and quality of the formed scar [10]. An insufficient amount of nucleic acids in the wound secretion cells is one of the important causes of regeneration failure, it may cause a delay in the development of granulation tissue, epithelialization and inadequacy of healing, as well as reduction of immunogenic properties of cells. Also skin dehydration can induce profound changes in the structure and in the biochemical processes occurring in the epidermis [11-14]. Thus, low humidity causes an increase in the amount of DNA synthesized and hyperproliferation of cells in the epidermis, up to the development of cellular hypertrophy [15]. Dehydration of granulation tissues leads initially to the over matured granulated tissues and its delayed formation, then to scarring and termination of epithelialization [16].

The modern scientific study of skin barrier properties indicates that ceramides play an important biological role. They are structural components of the stratum corneum, cell membranes and function as bioelectric molecules involved in cell proliferation and differentiation [17-20]. That's why the development of new ceramide-containing preparations is very crucial for improving efficiency and safety in the treatment of skin disorders.

The aim of the work was to study the effect of the cream containing dexpanthenol and ceramide on the proliferation and regeneration processes of burn wounds in rats.

2. MATERIALS AND METHODS

Experiments were performed on 84 white, outbred male rats weighing 200-240 g. Experimental animals were divided into

5 groups: 1 group - intact control (n = 6); 2 group - animals that were withdrawn from the test in the day after burn modeling (peak

of pathology) (n = 6); 3 group - control pathology (animals were not treated) (n = 18); 4-6 groups - animals treated with cream with ceramides, cream with dexpanthenol and ceramides and cream "Bepanten" (n = 18) respectively. A thin layer of creams was applied 1 time daily on the surface of the burn in the conditional therapeutic dose of 15 mg/cm² until the complete healing of the wounds. The technology of these medications and their composition were developed under the guidance of prof. N.A. Lyapunov (Derzhavniy Naukoviy Institute "Science and Technology Complex" Institute of Monocrystals of the National Academy of Sciences of Ukraine "(Kharkiv). Clinical observations of burn wounds healing processes in animals were carried out each alternate day. During this period the following parameters were evaluated: the conditions and areas of the wounds, as well as the terms of their complete healing. Animals were treated in accordance with generally accepted bioethical standards in compliance with the relevant international regulations for experimental studies using laboratory animals.

The burn injuries were simulated on the depilated area of the back skin, not far from the spine of anesthetized animals. A burn device comprises of a set temperature scale and an electric soldering device with a circular metal plate (d= 2.5 cm) attached at the end. The exposure time of the contact plate warmed up to 200 °C was 10 s [21]. This method allowed to receive standard burn size and depth that corresponds to the III-A degree of clinical classification of burns.

3. RESULTS

Simulation of a burn injury in rats results in the formation of dark brown color dense scab with a clearly limited necrosis area (574.8-731.5 mm²) and marked inflammatory changes in surrounding tissues (Table 1) on the skin. No animals' death was reported during the entire experiment.

The analysis of the obtained data showed that wound healing within 5 days in the control group was slow which is confirmed by a decrease of the wound area to 455.0 mm². Starting from the 7th day, wound healing was more intensive. Full wound reparation was recorded in 16.7% of the animals from the 19th day in the control group and 100% wound epithelization was observed on the 25th day of treatment.

The abovementioned results showed that the creams possess marked wound healing properties. Thus, a significant reduction of the burn area in animals that were treated by creams with ceramides and creams with dexpanthenol and ceramides was observed from the 3rd day of treatment relative to the initial data and from the 7th day in relation to the control group. Application of "Bepanten" cream showed notable results from 5th day of treatment with respect to the initial data as well as to the control group (Table 1). Complete epithelization of burns was observed in 16.7% of animals from the 15th day of the treatment by dexpanthenol and ceramides cream and from the 17th day of the treatment by creams containing ceramide and Bepanten - 16.7% and 33.3% respectively. In all animals, complete burns healing under the influence of cream containing dexpanthenol and ceramides were observed on the 19th day of treatment that is 6 days earlier compared with the control group. In its turn cream with ceramides and "Bepanten" cream demonstrated healing on

The study of proliferative-regenerative activity of investigated creams containing dexpanthenol and ceramides in the treatment of burns was carried out by immune-histochemical analysis. The content of the Ki-67 production cells and the RNA content in the cytoplasm of the granulation tissue fibroblasts were measured by the activity of proliferation and regeneration processes in the wound [22, 23]. Immune-histochemical analysis using Ki-67 antibodies of rabbits was conducted for the study of the proliferative activity of investigated drugs in the treatment of thermal burns. FITC-conjugated guinea pig anti-rabbit IgG secondary antibodies were used for the identification of antigen-antibody complex. The luminosity of the skin epithelial cells and its derivatives, i.e., the proliferative activity of these cells was evaluated using computer images obtained on the Axioscop-40 microscope (Zeiss, Germany), by determining the relative units of the luminescence brightness [22]. The skin samples were stained with gallocyanin according to Emerson methodology for the RNA content evaluation in the cytoplasm of granulated tissue fibroblasts. The number of RNA in the cytoplasm was calculated cytophotometrically. The optical density of the cytoplasm was determined using a computer image of the micropreparations obtained by the Axiostar-plus microscope and expressed in the relative units of optical density. The research results are processed using the "Statistica 6.0" program. The reliability of the intergroup difference was established using parametric and non-parametric methods at a significance level of p < 0.05.

the 21st day of treatment, which is 4 days earlier compared with the control group.

Immunohistochemical studies have shown an activation of the proliferative activity of epithelial cells in the basal layer of the epidermis. It was evaluated by the presence of Ki-67-expression (Fig. 1a) after burn simulation on the 9th day of the experiment in the control group at the periphery of the wound defect. In addition, activation of epithelial cell proliferation was detected in preserved hair follicles. Besides that, numerous large oval-shaped, brightly-lit cells, i.e., fibroblasts, have been detected in the depths of the wound, where the granulation tissue is formed. Ki-67 expression endothelial cells are also present along the contour of capillaries of granulation tissue.

The treatment by cream with ceramides on the 9th day causes the dominance of the surface epithelium as well as epithelium of the hair follicles along the periphery of the wound in the proliferative process (Fig. 1b). It was observed that the quantity of Ki-67-expressing cells in the basal layer of the epidermis was greater than in the control group. The overall thickness of the epidermis was significantly increased.

Studying of micro preparations in animals treated with dexpanthenol and ceramides, showed that Ki-67-expressing cells are mostly found in the epithelial layer, crawling into the wound, in the skin derivatives around a wound that has smaller dimensions (Fig. 1c). The proliferative activity of fibroblasts was slightly reduced, which could be explained by stimulation of maturation of granulated tissue. The mechanism of rapid maturation of granulation tissue could be associated with a decreased severity of the secondary alteration in the wound after delivery of exogenous pro-vitamin B3, which makes any cells

more resistant to the process of degeneration and, accordingly, | apoptosis.

Table 1. Dynamics of wound area (mm²) in the treatment by investigated creams on model of burn wounds in rats, n = 6.

Days of treatment	Experimental groups			
	Control group	Cream with ceramides	Cream with dexpanthenol and ceramides	Cream "Bepanten"
Output data	575.8 ± 48.41	603.3 ± 34.91	731.5 ± 47.37	574.8 ± 36.49
5 th	455.0 ± 33.11	415.0 ± 26.12*	426.2 ± 28.05*	358.7 ± 26.12 ^{*/**}
7 th	379.0 ± 19.75*	303.0 ± 25.94 ^{*/**}	296.5 ± 24.11 ^{*/**}	274.0 ± 19.56 ^{*/**}
9 th	267.5 ± 37.62*	221.8 ± 21.79*	198.3 ± 24.14*	200.8 ± 18.69*
13 th	170.8 ± 44.02*	47.8 ± 7.64 ^{*/**}	42.0 ± 11.49 ^{*/**}	68.7 ± 10.08 ^{*/**}
15 th	126.3 ± 38.82*	23.0 ± 4.47 ^{*/**}	13.2 ± 3.94 ^{*/**}	27.8 ± 5.15 ^{*/**}
17 th	61.3 ± 19.50*	7.7 ± 3.44 ^{*/**}	3.0 ± 1.44 ^{*/**}	8.7 ± 2.35 ^{*/**}
19 th	20.3 ± 6.76*	1.7 ± 0.67*	–	2.0 ± 0.89*

Note: * - the deviation is valid with respect to the initial values, p<0.05; ** - the deviation is valid with respect to the control group, p<0.05; n - the number of animals in the group.

Table 2. Dynamics of the intensity of the glow of Ki-67-expressing cells (relative units) in the treatment of thermal burns by the investigational drugs.

Experiment groups	Days of treatment	
	9th day	18th day
Control group	1.05 ± 0.010	0.365 ± 0.010
Cream with ceramides	1.12 ± 0.005*	0.618 ± 0.007 ^{*/**}
Cream with dexpanthenol and ceramides	1.26 ± 0.010*	0.672 ± 0.002 ^{*/**}
Cream "Bepanten"	1.23 ± 0.010*	0.494 ± 0.010*

Note: * - the deviation is valid with respect to the control group, p<0.05;

** - the deviation is valid with respect to the reference preparation "Bepanten" cream, p<0.05.

Table 3. Dynamics of the content of RNA in the cytoplasm of fibroblasts (relative units) on the model of burn wound in rats.

Experiment groups	Days of treatment	
	9th day	18th day
Control group	1.05 ± 0.010	0.365 ± 0.010
Cream with ceramides	1.12 ± 0.005*	0.618 ± 0.007 ^{*/**}
Cream with dexpanthenol and ceramides	1.26 ± 0.010*	0.672 ± 0.002 ^{*/**}
Cream "Bepanten"	1.23 ± 0.010*	0.494 ± 0.010*

Note: * - the deviation is valid with respect to the control group, p<0.05; ** - the deviation is true with respect to cream with ceramides, p <0.05.

During the treatment of the burn wound with "Bepanten" cream, an increased number of Ki-67-expressing endothelial cells and epithelial cells was observed, indicating an enhancement of the proliferative activity of these cells (Fig. 1 d). The reduced total number of labeled fibroblasts can be interpreted as the result of accelerated formation and start of maturation of granulated tissue in this study period. Therefore, the "Bepanten" cream stimulates the burn healing by the formation of a scar and epithelization.

The appearance of sites in the thickness of the wound bottom, completely devoid of Ki-67 antigen positive cells was recorded on 18th day in animals of the control group (Fig. 1e). A specific glow was observed in fibroblasts and capillary endothelial cells of immature granulated tissue. In the group of animals treated with ceramide cream, the proliferation of epithelial cells in the epidermis and hair follicles was stimulated in a greater degree compared to the control group (Fig. 1f). This granulated tissue is better compare with the control group according to the level of Ki-67 antigen-positive cell.

Under the treatment by dexapanthenol and ceramide containing cream for burn wound healing, a young and mature granulation tissue is well differentiated. It could be explained by the termination of new capillaries formation since in a tissue at the bottom of the wound. The epidermis almost completely regenerated along the wound surface. The content of Ki-67 antigen-positive cells in the basal layer of the epidermis decreased, while the proliferation of epithelial cells in the hair follicles was active (Fig. 1g).

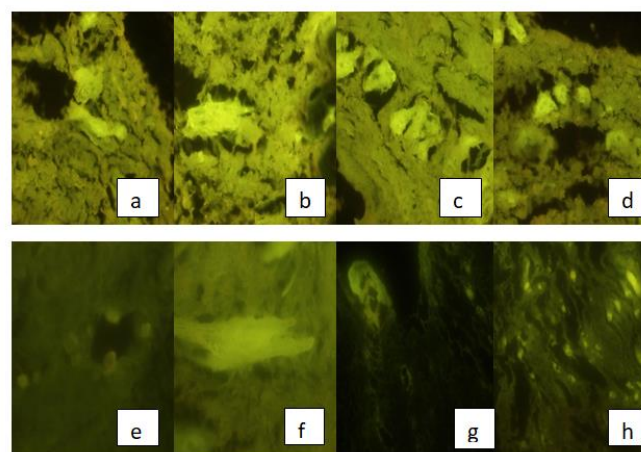


Figure 1. Ki-67-expressing cells of granulated tissue at burn wounds of the skin on the 9th and 18th day of the experiment in the control group (a and e), in the group of animals treated with cream with ceramides (b and f), cream with dexpanthenol and ceramides (c and h), "Bepanten" cream (d and j). Immune-histochemical reaction with Ki-67 antibodies. Fluorescent microscopy x 100.

A general increase in the number of Ki-67 antigen-positive cells in both peripheral layers of the epithelium (in the basal layer) and in the active granulation tissue, was observed in the group of animals treated by "Bepanten" cream. Secondary alteration during the development of inflammation could be caused by the decrease of dead tissue volume (Fig. 1h).

A histometric determination of the luminescent glow brightness of Ki-67-expressing epithelial cells was performed for

the determination of the proliferative activity in the skin epithelial cells (Table 2). It was found that the intensity of the luminosity was higher 1.1-1.2 times compared with the control group on the 9th day of the experiment in all treatment groups.

Ki-67-expressing cells were represented not only by different amounts but also by different brightness of the luminescent glow on the 18th day of burn wounds treatment (Table 2). It reflects the average expression of Ki-67 proliferation antigen level in the cell. Compared with the control group, it was significantly increased by 1.4 times in the group of animals treated with "Bepanten" cream, even more (1.7 times) in the group of animals treated with cream with ceramides and maximally increased (in 1.8 times) in a group of animals treated with cream with dexpanthenol and ceramides. It should be noted that the proliferative effect of the cream with ceramides and cream with dexpanthenol and ceramides was significantly higher 1.3 and 1.4

4. CONCLUSIONS

Thus, studies have shown that ceramides contribute to the healing of wounds, increase the content of Ki-67 antigen positive cells, especially among epithelial cells (epidermis, derivatives). Addition of ceramides to dexpanthenol is rational, since they have a distinct wound healing effect, which allows simultaneously to

5. REFERENCES

1. Loyd, E.C.; Rodgers, B.C.; Michener, M.; Williams, M.S. Outpatient burns: prevention and care. *Am. Fam. Physician* **2012**, *1*, 25–32.
2. Ghieh, F.; Jurjus, R.; Ibrahim, A.; Geagea, A.G.; Daouk, H.; Baba, B.E.; Chams, S.; Matar, M.; Zein, W.; Jurjus, A. The use of stem cells in burn wound healing : a review. *BioMed. Research International* **2015**, *10*, 684–693, <http://dx.doi.org/10.1155/2015/684084>.
3. Wang, Y.; Beekman, J.; Hew, J.; Jackson, S.; Issler-Fisher, A.C.; Lajevardi, S.S.; Li, Z.; Maitz, P. K. M. Burn injury: Challenges and advances in burn wound healing, infection, pain and scarring. *Advanced Drug Delivery Reviews* **2018**, *123*, 3-17. <https://doi.org/10.1016/j.addr.2017.09.018>.
4. Azevedo, F.F.; Moreira, G.V.; Gabriela Virginia Moreira; Teixeira, C.J.; Lima, M.H. Topical Insulin Modulates Inflammatory and Proliferative Phases of Burn-Wound Healing in Diabetes-Induced Rats. *Biological Research for Nursing* **2019**, *21(5)*, 473-484, <https://doi.org/10.1177/1099800419864443>.
5. Kondratenko P.G. Treatment of wounds. Surgery. *Medicine: Kiyv, Ukraine*, **2009**; 836. (In Ukrainian)
6. Greenhalgh, D.G. Management of Burns. *N Engl J Med*. **2019**, *13*, 2349-2359, <https://doi.org/10.1056/NEJMra1807442>.
7. Zhou, D; Fu,H; Liu, S; Zhang, L; Xiao, L; Bastacky, SI; Liu, Y. Early activation of fibroblasts is required for kidney repair and regeneration after injury. *FASEB J*. **2019**, *28*, <https://doi.org/10.1096/fj.201900651RR>.
8. Kpelao, E.; El Kader, M.; Anthony, B.; Alain, A.; Agbeko, D.; Hobli, A.; Komi, E. ;Essolim, B. and Anani, A. Technique of Granulation Tissue Genesis from Diploe. *Modern Plastic Surgery*, 2018, **8**, 9-14. <https://doi.org/10.4236/mps.2018.82002>.
9. Hirotsu, K; Kannan, S; Brian Jiang SI. Treatment of Hypertrophic Granulation Tissue: A Literature Review. *Dermatol Surg.*, **2019**, *8*, S226, <https://doi:10.1097/DSS.0000000000002059>.

times, respectively in comparison with the action of the reference preparation "Bepanten" cream.

The analysis of the results showed that the greatest acceleration of the scar formation in the thermal wound occurred after application of cream containing dexpanthenol and ceramides and "Bepanten" cream (Table 3). This is due to the fact that fibroblasts contain a maximum amount of RNA in the cytoplasm – 0.304 ± 0.008 and 0.336 ± 0.007 relative units.

On the other hand, conducted immune-histochemical studies on Ki-67-expressing cells showed that proliferative activity of young cells of the epidermis and its derivatives sharply increases in the wound, which provides more complete regeneration than was seen in the control group. On the 18th day of treatment by dexpanthenol and ceramides cream, active fibroblasts in the granulation tissue were present only in the upper layers, as the lower granulation tissue has already matured and turned into scar tissue.

affect the various parts of the wound process, improving quality and reducing the wound healing time. The therapeutic effect of the cream with ceramides is not inferior to the action of "Bepanten" cream.

10. Tkacheva, O.V.; Butko, Y.A. Burns of the skin: classification and methods of treatment. *Provizor* **2008**; *2*, 23-28. (In Russian)
11. Velnar, T.; Bailey, T.; Smrkolj V. The wound healing process: an overview of the cellular and molecular mechanisms *J. Int. Med. Res.* **2009**, *37*, 1528–1542, <https://doi.org/10.1177/147323000903700531>.
12. Strong, A.L.; Neumeister, M.W.; Levi, B. Stem cells and tissue engineering: regeneration of the skin and its contents. *Clin Plast Surg.* **2017**, *44*, 635–50. <https://doi.org/10.1016/j.cps.2017.02.020>.
13. Li, M.; Zhao, Y.; Hao, H.; Han, W.; Fu, X. Theoretical and practical aspects of using fetal fibroblasts for skin regeneration. *Ageing Res Rev.* **2017**, *36*, 32–41. <https://doi.org/10.1016/j.arr.2017.02.005>.
14. Vig, K.; Chaudhari, A.; Tripathi, S.; Dixit, S.; Sahu, R.; Pillai, S.; Dennis, V.A.; Singh, S.R. Advances in Skin Regeneration Using Tissue Engineering *Int J Mol Sci.* **2017**, *18(4)*, 789. <https://doi.org/10.3390/ijms18040789>.
15. Syarina, P.; Karthivashan, G.; Abas, F.; Arulselvan, P.; Fakurazi, S. Wound healing potential of spirulina platensis extracts on human dermal fibroblast cells. *EXCLI Journal* **2015**, *3*, 385–393, <https://doi.org/10.17179/excli2014-697>.
16. Lohmeyer, J.A.; Liu, F.; Kruger, S.; Lindenmaier, W.; Siemers, F.; Machens, H.G. Use of gene-modified keratinocytes and fibroblasts to enhance regeneration in a full skin defect. *Langenbecks Arch. Surg* **2011**, *2*, 76–79, <https://doi.org/10.1007/s00423-011-0761-3>.
17. Mohan, G.C.; Lio, P.A. Comparison of Dermatology and Allergy Guidelines for Atopic Dermatitis Management. *JAMA Dermatol* **2015**, *151*, 1009-13.
18. Benayahu, D.; Sharabi, M.; Pomeranec, L.; Awad, L.; Haj-Ali, R.; Benayahu, Y. Unique Collagen Fibers for Biomedical Applications. *Mar. Drugs* **2018**, *16*, 102, <https://doi.org/10.3390/md16040102>.
19. Myeongkwan Song, Sekyung Kim, Hyun Shik Yun, Soonjo Kwon. Anti-inflammatory effect of the ceramide mixture

extracted from genetically modified *Saccharomyces cerevisiae*. *Biotechnolodgy and Bioprocess Engineering* **2017**, *22* (5), 653 – 658.

20. Jungersted, J.M.; Hellgren, L.I.; Høgh J.K.; Drachmann, T.; Jemec, G.B.E.; Agner, T. Ceramides and barrier function in healthy skin. *Acta Derm.Venereol* **2010**, *4*, 90, 350–353, <https://doi.org/10.2340/00015555-0894>.

21. Iakovlieva, L.V.; Tkachova, O.V.; Butko, Y.O.; Laryanovskaya, Y.B. Experimental study of new drugs for local

wound healing. *SEC Ministry of Health: Kiiiv, Ukraine* **2013**; *52*. (In Ukrainian)

22. Gubina-Vakulyk, G.I.; Sorokina, I.V.; Markovsky, V.D. Method of quantitative determination of the antigen content in biological tissues Patent of Ukraine 46489, **2009**, *4*. (In Ukrainian)

23. Prokhorov, D.V. The role of markers of cellular renewal (Vsl-2, p-53) and proliferation (Ki-67) in the diagnosis of malignant melanocytic neoplasms of the skin. *Ukr. Journ. Dermatology, venereology, cosmetology* **2013**, *4*, 31-36. (In Russian)



© 2019 by the authors. This article is an open access article distributed under the terms and conditions of the Creative Commons Attribution (CC BY) license (<http://creativecommons.org/licenses/by/4.0/>).